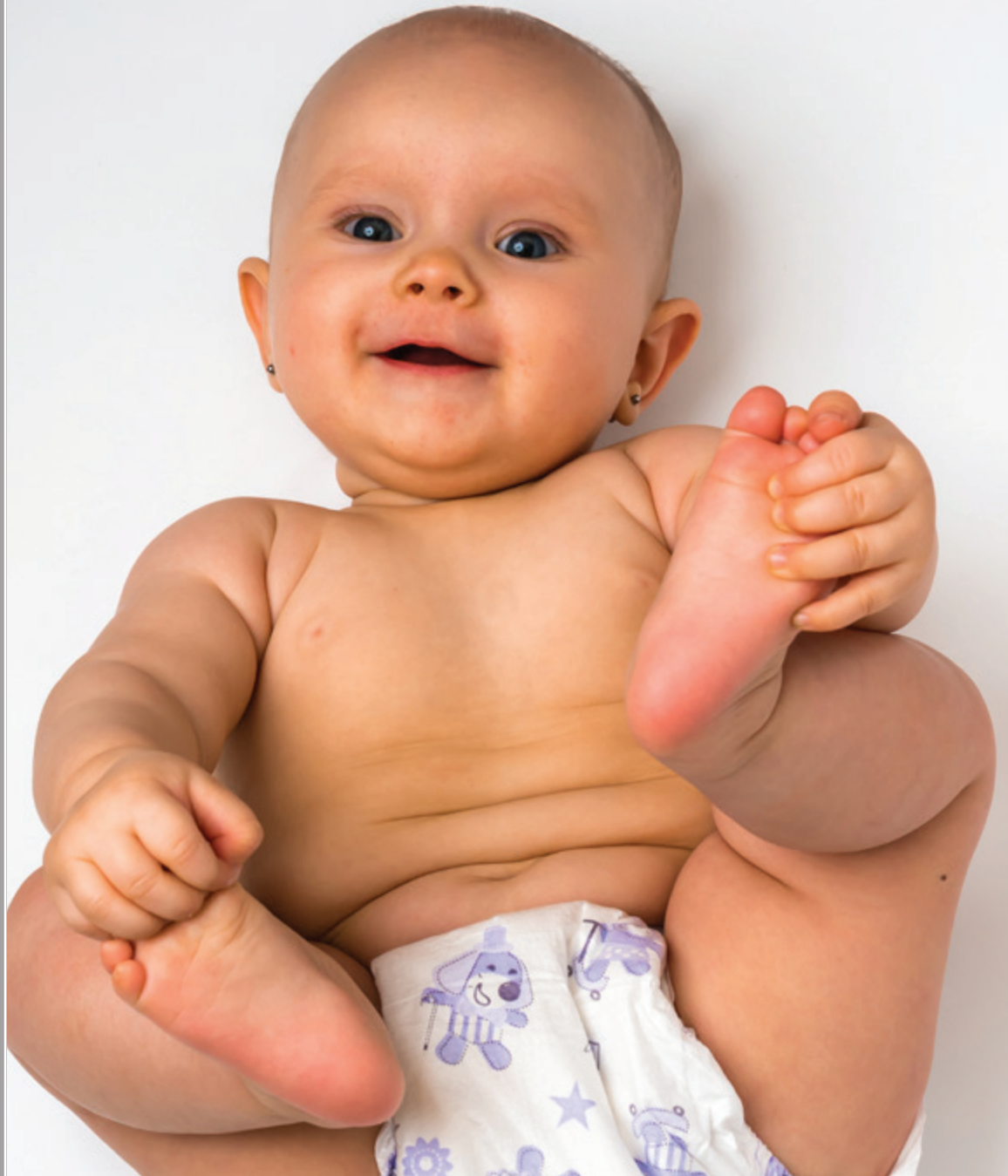



# Infant Laser-Assisted Lingual Frenotomy

---

A Case Study

*By Linda Murzyn-Dantzer, DMD*

**BIOLASE**

## Abstract

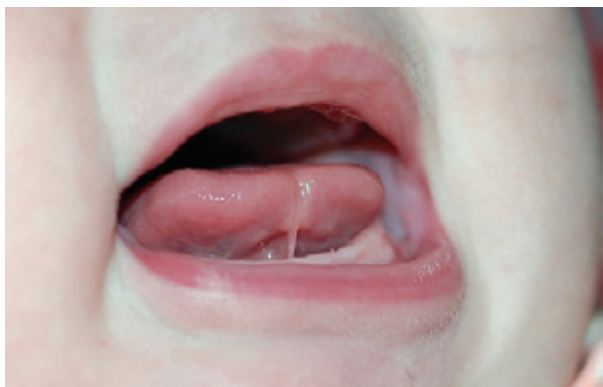The purpose of this clinical case study is to present dental practitioners with the benefits and techniques of laser-assisted lingual frenotomy on infants. Ankyloglossia (tongue-tie) is a thickened, tightened, or shortened frenum which limits movement of the tongue. In infants, this restriction of movement is a concern, because it can impede nursing or bottle feeding. Frenotomy is the incision and the relocation of the frenal attachment and can be accomplished by scalpel technique, scissor technique, electrosurge, or with lasers. In this case study, an Er,Cr:YSGG 2,780 nm laser is used (Waterlase MD, BIOLASE Inc., Irvine, Calif.)

## Armamentarium

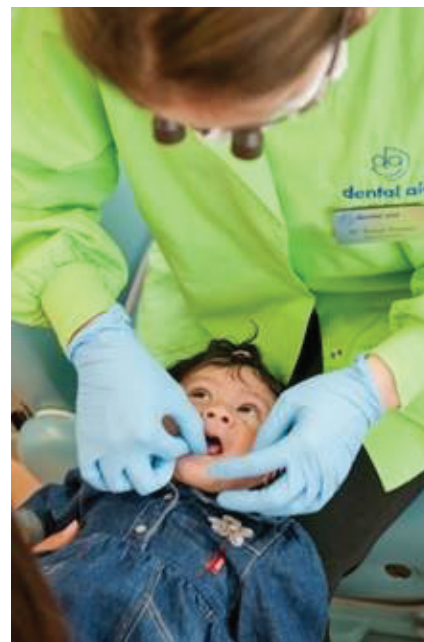
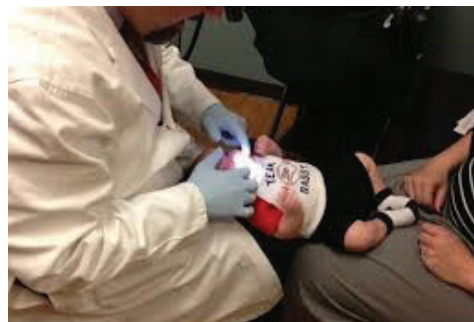
Materials used included a grooved tongue director; an Er,Cr:YSGG laser, protective eye-wear (laser-specific), surgical suction, and gauze.

## Case Presentation

A four-week old healthy, full-term female presented with Type III ankyloglossia based on the Coryllos classification. This is described as thick, fibrous, and not elastic frenulum; the tongue is anchored from the middle of the tongue to the floor of the mouth. Although the tongue could extend past the lower ridge, the tongue posture was never elevated, even during crying. Functional clinical criteria either observed or reported by the mother included shallow and unsustained latch, “gumming” at the nipple, gassiness, colic and reflux. There was also a report of maternal pain during and after nursing and that the baby also had difficulty feeding from a bottle.



*Figure 1. Example of tongue posture.*



*Figure 2. Examples of lap-to-lap position.*

### **Diagnosis:**

Type III ankyloglossia. The location and quality of the lingual frenum was preventing the tongue from lifting to the roof of the mouth and performing at an optimal level.

### **Treatment Plan**

Laser-assisted lingual frenotomy was recommended to release the tongue for optimal function. Short-term benefits of improved nursing and reduction of pain and other symptoms were discussed with parent. Long-term benefits of decreased caries risk, possible reduced speech or orthodontic problems were also discussed. The importance of post-frenotomy stretching exercises to prevent reattachment, optimize healing, and create muscle memory was emphasized to the parent.

## ***Treatment Methodology***

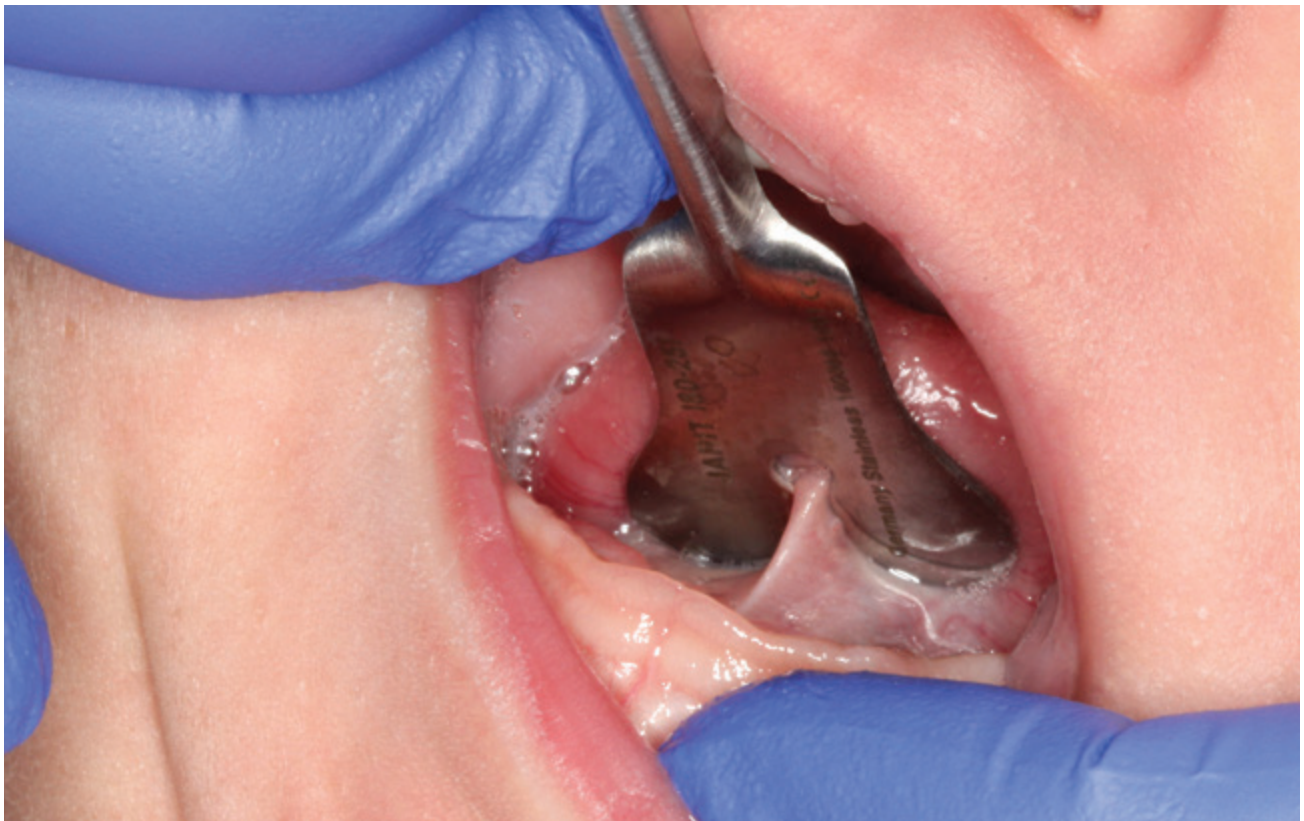With the treatment of any infant, patient management is of primary importance. In this case, the infant was placed directly on the mother's lap, while the clinician sat facing the mother. The infant's head was turned towards the clinician while the mother managed the infant's body movements. A dental assistant was also present. Protective eye-wear was worn by the patient and all other participants.

No local anesthesia was administered for this case. This provider chose not to use an injectable anesthetic for laser-assisted infant cases because it interferes with post-operative nursing and can potentiate other complications. Provider is also very careful not to use certain drugs on very young patients. One such drug is Benzocaine, a common topical anesthetic that has the potential to cause Methemoglobinemia, a blood disorder in which an abnormal amount of methemoglobin -- a form of hemoglobin -- is produced. Hemoglobin is the protein in red blood cells that carries and distributes oxygen to the body. With methemoglobinemia, the hemoglobin can carry oxygen but is

unable to release it effectively to body tissues. Other drugs have been implicated to cause blood and tissue disorders as well.

If anesthetic is needed, this provider will choose a compounded topical (Lidocaine, Tetracaine, and Phenylephrine) to be used sparingly in the release area and prevent it from being swallowed by the patient.

Although a scalpel, scissors, electrosurge or diode laser could be utilized to perform the frenotomy, the Er,Cr:YSGG laser was selected for its ability to rapidly ablate soft tissue, along with an associated analgesic effect, hemostatic capabilities and minimal patient discomfort. The Er,Cr:YSGG laser has the capability of keeping the target tissue cool and relaxed while cutting rapidly; this is accomplished via a combination of water-cooling and pulsing of laser energy. Er,Cr:YSGG lasers help make frenotomy treatment significantly less traumatic for both patient and parent. Healing is faster and usually uneventful with the laser and there are no sutures to be removed from scalpel or scissor use.



**Figure 3.** Type III ankyloglossia: A grooved tongue director allowed the operator to access the area and demonstrate the problematic area to the parent.



Additionally, the laser is preferred for reasons of safety. It is common for infants to produce sudden involuntary movements. If a scalpel, scissor, or an electrosurge were being used, the infant could be injured if they suddenly move into the instrument zone. With the laser, the operator can immediately stop the energy transfer with the foot pedal so the patient cannot hurt themselves. This is a comforting safety feature for the clinician as well as for the parent who is an active participant in treatment.

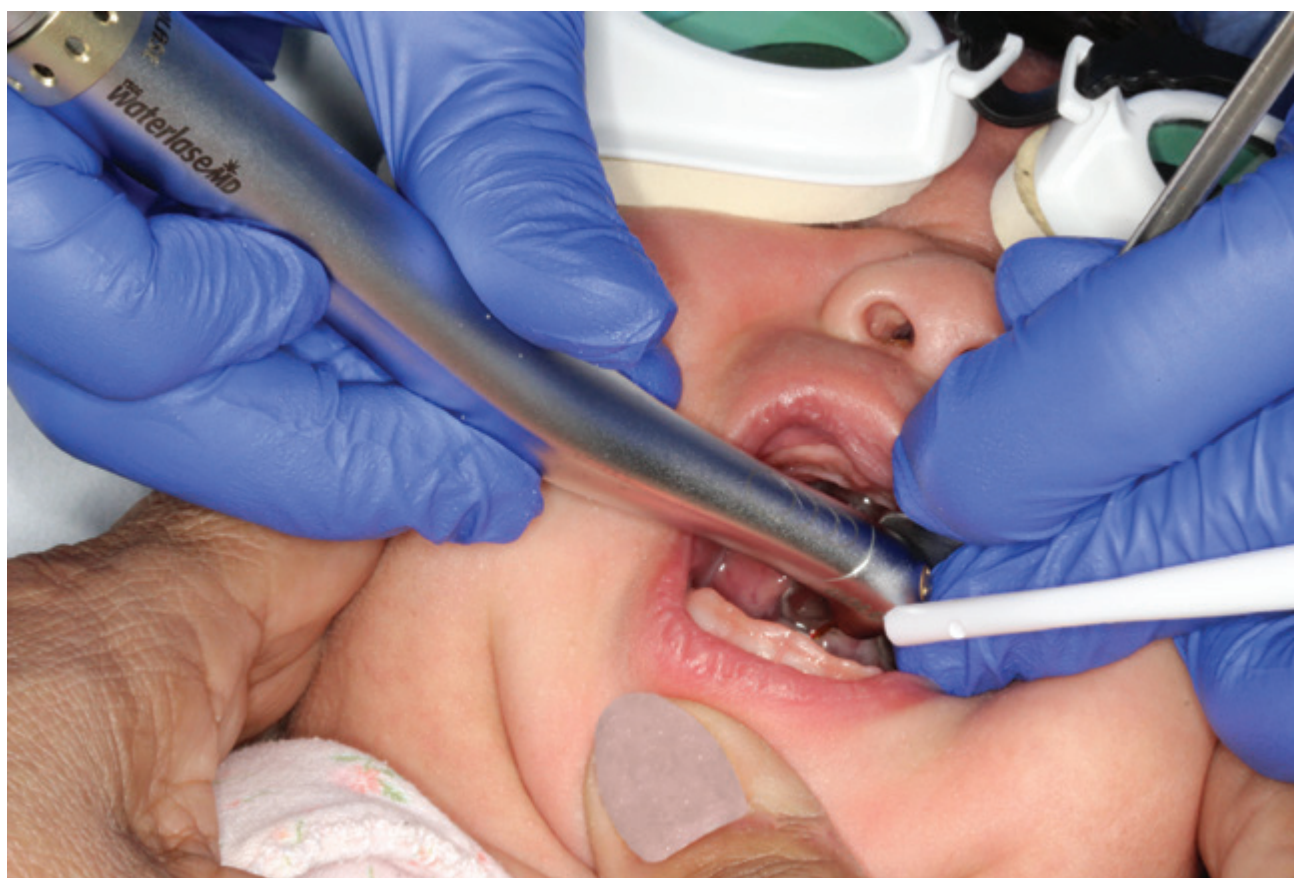Often there are two components in the lingual frenum. The first may be a more visible anterior component that may be thick or thin and extends from near or at the tip of the tongue to the floor of the mouth or to the lower ridge. The major restriction in tongue movement stems from the base of the tongue, and this is considered the posterior tongue tie. Clinicians should be aware that there may be several branches of fibers, and all of these branches require relief.

While the tongue was held and reflected upward and posteriorly to create tension, the Er,Cr:YSGG laser with

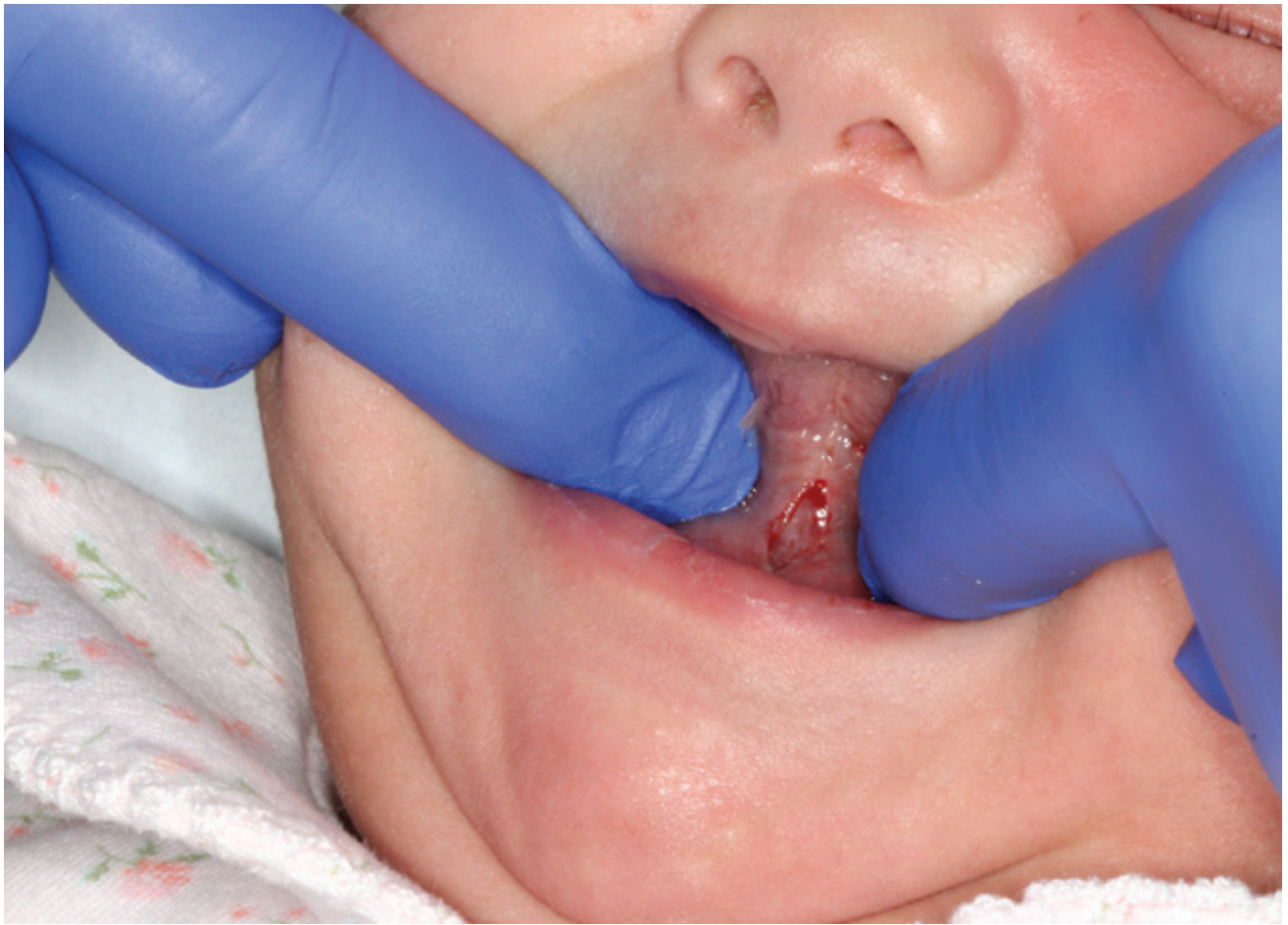Gold hand piece was utilized to incise the frenum on the underside of the tongue (laser setting 2.75W, 50Hz, 20% water, 20% air with an MZ5 tip) without contacting the tissue. The laser tip was kept approximately 0.5-1mm from the tissue to be ablated. This created a clean, fine incision with very little bleeding. Total time utilizing the laser to complete the frenotomy was approximately 1 minute.

After the incision of the frenum, hemostasis was achieved with minimal gauze pressure. No hemostatic agents were required as the laser technique produced minimal bleeding. The laser bandage setting (0.5 W, 30HZ, 10% air and no Water) can be used if necessary.

After the laser procedure, the release was observed and the patient's tongue could be lifted to the upper ridge without restriction. In resting position, the tongue was flat and there was no more pull from that area to the floor of the mouth.



**Figure 4.** The clinician performs the frenotomy with the laser, while managing the patient's tongue with a grooved tongue director. The dental assistant manages aspiration, while the parent (pictured gloveless) works together with the clinical team to manage patient mobility.



*Figure 5. Immediately post-op. No hemostatic agents were required. This is the bleeding in its entirety showing how minimal it was. Wound care exercise shown with two fingers*

Stretching exercises were performed immediately after the procedure. Stretching the tongue starts the healing process and provides muscle memory to the area. A thorough explanation and demonstration of stretching exercises was given to the parent, and the importance of the exercises to prevent reattachment was emphasized. The patient was discharged after she showed function.

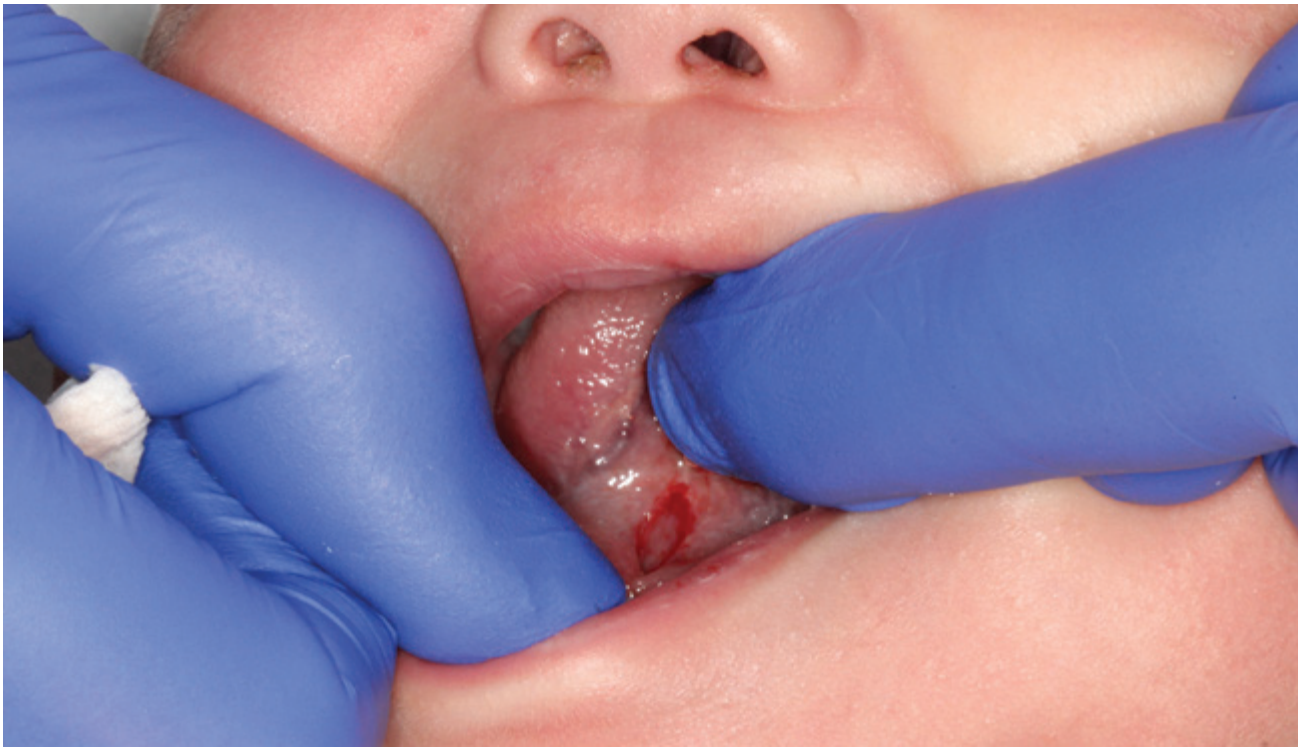### **Post-op**

The patient exhibited immediate improvement in tongue mobility immediately after treatment. The parent was given post-operative instructions and mobility exercises for the patient. The purpose of the exercises is to keep the tongue active and prevent reattachment or scarring. Exercise instructions were as follows: Perform the stretching exercises as shown 1-2 times before every daytime nursing or feeding (if by bottle), or at least every 4 hours, for two

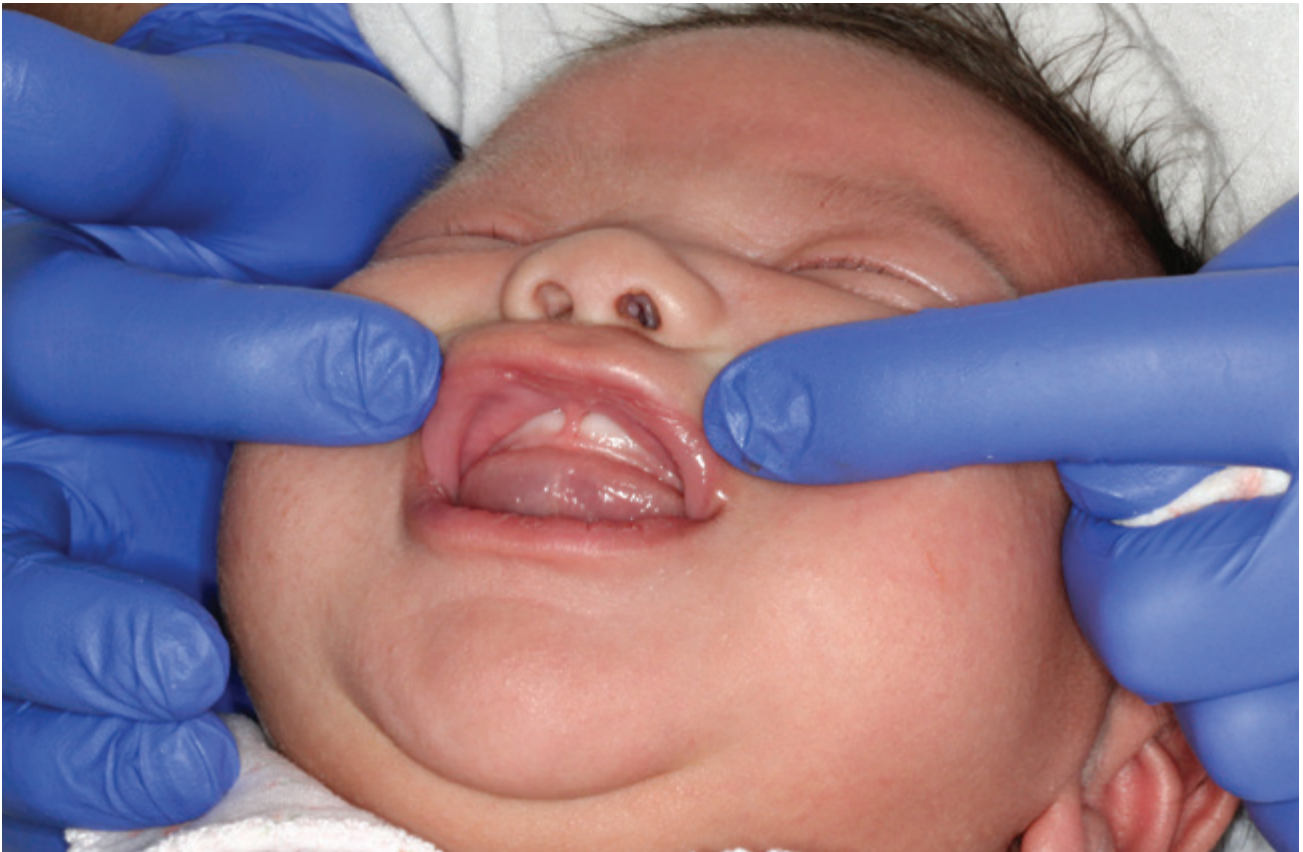weeks. Exercises are especially important within the first 48 hours but care is taken to not be overly aggressive inside the wound itself. The parent is instructed to position the baby in the same manner as the procedure was performed (lap-to-lap or lying on a bed or changing table). Using the pads of one or both index fingers, slide the finger(s) on the underside of the tongue on the sides of the wound area to the base and lift the tongue to expose the diamond-shaped wound. Hold this position for a count of three, release and then repeat one or two more times.

The parent was educated about the recovery process. Fussiness can be expected in the beginning. Also, a small white patch is expected to develop at the revision site within the first 24-48 hours, which is normal and is not an infection, pus, or thrush. Over the next two weeks, this tissue will mature, recontour, and take on normal appearance and color.





*Figure 6. Post op, the tongue is released. Wound care exercises shown with one finger on tongue and one on ridge.*



*Figure 7. Immediate post op, the patient is able to lift the tongue to the upper ridge without restriction.*

The mother of the child is encouraged to nurse immediately after the procedure, although should not be discouraged if the baby is disinterested. A return visit to a lactation consultant is highly recommended. As young as they are, infants learn habits to accommodate and may need to be retrained to nurse properly.

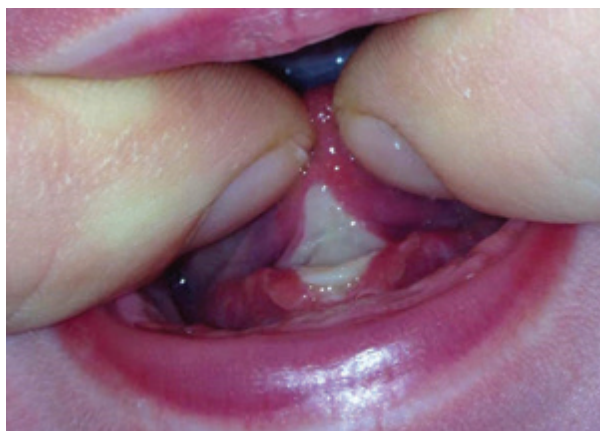Post frenotomy, there is no contraindication to feeding or use of a pacifier. OTC Tylenol can be used after the procedure, but normal calming techniques are encouraged first, and breast milk can be the best medicine.

## Conclusion

The restriction of the tongue was eliminated and the tongue stretched to the ridge on top and extended beyond the ridge (which was not possible prior to the frenotomy). No anesthetic was used, so the infant was able to function immediately after treatment. The mother was happy because when she took the infant back to the breast, comfort was achieved for the first time. The patient also took to the bottle without the reflux that was previously experienced. The patient was able to drink continuously without the need to take a break.

## Discussion

Frenotomy for ankyloglossia is medically necessary when newborn feeding difficulties exist. The laser can help make frenotomy treatment significantly less traumatic for both patient and parent. Healing is expedited and usually uneventful.



**Figure 8.** The white patch is the wound site indicating that the release has been accomplished.

## Advantages of Laser for Infant Frenotomy:

- ✦ No local anesthetic required
- ✦ Less topical anesthetic required
- ✦ Less analgesic required
- ✦ No allergic or drug interactions
- ✦ Short operative time
- ✦ Significantly reduces risk of bleeding because of hemostatic properties of laser
- ✦ More precise control; if baby moves, tongue is not cut
- ✦ Reduces post-surgical swelling, pain, discomfort
- ✦ Starts healing through initiating biologic pathways
- ✦ Bactericidal properties of laser mean reduced chance of infection

In addition to mobility and restored function, long-term prognosis for frenotomy is decreased risk of dental caries. This is true for both lingual and maxillary frenum issues. The tongue helps clean the mouth. It involuntarily explores teeth and gums to help release food particles. If the tongue is not restricted, it sweeps up during and after meals. If the tongue can't remove debris from an area, then a higher cavity risk presents itself. For the maxillary frenum, if the patient cannot lift the lip easily to get a toothbrush in there, then food and debris will deposit on the cervical area of the upper teeth and present a higher cavity risk if not wiped or brushed away.

Infant frenotomy may also have positive long-term orthodontic implications. The tongue is utilized throughout the entire mouth and can change an orthodontic profile. For instance, depending on the severity of the tongue-tie, a patient could have a different growth of the jaw because it is restricted in certain dimensions. In addition, the tongue is a natural palatal expander. If the tongue is not allowed to touch the roof of the mouth, and the swallow doesn't mature, the palate remains narrow and vaulted. This means that teeth will erupt crooked with a lack of space and without room to grow.

## About the Author

Dr. Linda Murzyn-Dantzer started her career in dentistry as a dental assistant. After graduation from high school, she attended Forsyth School for Dental Hygienists in Boston, Massachusetts, and received a certificate in dental hygiene and an associate degree from Northeastern University. She went on to receive her DMD from the Harvard School of Dental Medicine. Dr. Murzyn-Dantzer completed her pediatric dental residency at the University of Michigan and is a Diplomate of the American Board of Pediatric Dentistry. She is currently an assistant professor at the University of Colorado and a full-time faculty member at Children's Hospital Colorado in the Denver area. Dr. Murzyn-Dantzer has attained Mastership Certification from the World Clinical Laser Institute (wcli.org).

## References

Walsh, L. J. "The current status of laser applications in dentistry." *Australian dental journal* 48.3 (2003): 146-155.

Olivi, Giovanni, et al. "Er, Cr: YSGG laser labial frenectomy: a clinical retrospective evaluation of 156 consecutive cases." *Gen Dent* 58.3 (2010): 126-133.

Martens, Luc C. "Laser-assisted Pediatric Dentistry: Review and Outlook." *Journal of Oral Laser Applications* 3.4 (2003).

Eversole, L. R., and I. Rizoiu. "Pulpal response to cavity preparation by an erbium, chromium: YSGG laser-powered hydrokinetic system." *The Journal of the American Dental Association* 128.8 (1997): 1099-1106.

Wang, Xiaogu, Chengfei Zhang, and Koukichi Matsumoto. "In vivo study of the healing processes that occur in the jaws of rabbits following perforation by an Er, Cr: YSGG laser." *Lasers in medical science* 20.1 (2005): 21-27.

